

Contemporary Strategies in Breast Reconstruction

Merisa L. Piper, MD, and Hani Sbitany, MD, FACS

Abstract

Improvements in neoadjuvant therapy have allowed more women to be candidates for breast-conserving therapy (BCT). “Oncoplastic” surgery, which combines plastic surgery techniques with oncology surgery, developed as a way to reconstruct defects that occur following partial mastectomy. A variety of oncoplastic techniques are available that primarily depend on breast size, tumor-to-breast ratio, degree of ptosis, and radiation history. Additionally, in those women who are not candidates for BCT and require mastectomy, modifications have been made to improve aesthetic and patient-reported outcomes. Care is taken to preserve the entire skin envelope and nipple areolar complex, and reconstruction focuses on creating a soft, natural breast. This review provides an overview of the various techniques for breast reconstruction. It also discusses which factors influence the reconstructive algorithm, and the outcomes of various techniques, with a focus on the influence of chemotherapy and radiation therapy on these outcomes.

Key words: breast reconstruction, oncoplastic surgery, partial mastectomy, breast-conserving therapy, immediate versus delayed breast reconstruction

Introduction

Over time, the surgical management of breast cancer has become less radical, as improved adjuvant therapy has allowed more women to be candidates for breast-conserving therapy (BCT). The development of “oncoplastic” surgery has accompanied this evolution. The term *oncoplastic surgery* broadly refers to the reconstruction of partial mastectomy defects immediately at the time of lumpectomy/partial mastectomy to provide improved aesthetic outcomes. Several different oncoplastic techniques have been described, including local tissue rearrangement, local-regional flap transfer, mastopexy (breast lift), and reduction mammoplasty. Growing evidence suggests that these techniques make breast conservation available to more women,^{1,3} provide better control of tumor margins,⁴ and result in improved aesthetic^{5,6} and patient-reported outcomes.^{7,9}

In patients with breast cancer who require mastectomy, sur-

geons now place greater emphasis on preserving the external nipple-areolar complex (NAC) and the entire breast skin envelope.¹⁰⁻¹³ At many institutions, nipple-sparing mastectomy or total skin-sparing mastectomy is now the standard of care for women who require mastectomy.¹⁴ Implant-based and autologous tissue reconstructions have evolved to provide a more natural appearance and feel to the reconstructed breast. These changes have led to higher patient satisfaction and improved aesthetic results.^{11,12,15,16} This, in turn, has led to higher rates of contralateral and bilateral prophylactic mastectomies in women who previously hesitated when aesthetic results were not as successful.¹⁷

Even with the greater focus on aesthetic and patient-reported outcomes and on breast conservation, equivalent oncologic safety has been maintained.^{14,18-20} This is partly attributed to the expanding use of chemotherapy and radiation therapy (RT).²¹ Both are critical components of breast cancer treatment, but markedly increase the complexity of reconstruction and influence the timing of reconstruction.^{22,23}

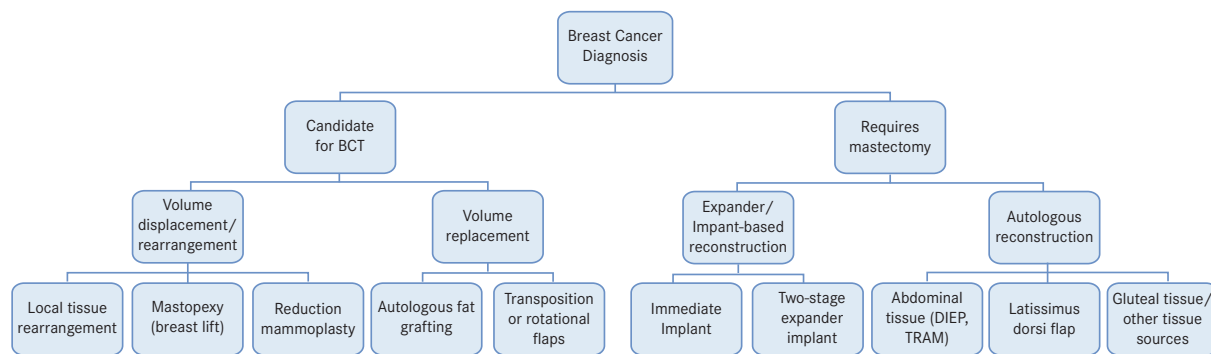
With regard to mastectomy and whole-breast reconstruction, chemotherapy will primarily affect the timing of the reconstructive process. RT will have a greater effect on the specific procedure chosen for breast reconstruction.²⁴ Ultimately, all of these factors combined will determine outcomes and dictate the rates of complications encountered throughout the reconstructive process. This review will highlight what interventions influence the reconstructive decision tree (**Figure 1**) and provide a comprehensive overview of associated outcomes.

Partial Mastectomy (Lumpectomy) Reconstruction

Repair of partial mastectomy defects is fundamentally categorized into 2 types: volume displacement/rearrangement and volume replacement.²⁵ Several algorithms for reconstruction of partial mastectomy defects have been proposed, factoring in breast size and shape, tumor location, timing of radiotherapy, and patient desires.²⁶

The most straightforward oncoplastic technique involves local tissue rearrangement.²⁵ This is reserved for patients with adequate breast tissue (B or C cup), minimal ptosis, sufficient skin, and small tumors.^{24,27,28} This involves a redistribution and rearrangement of the remaining breast tissue following lumpectomy, to prevent a large regional cavity. If there is insufficient adjacent tissue, local or regional soft-tissue flaps can be used, such as

FIGURE 1.



Reconstructive decision tree based upon whether a patient is a candidate for breast-conserving therapy (BCT) or requires mastectomy.

flaps from the subaxillary region or the latissimus dorsi flap.^{27,28}

Mastopexy (breast lift) and oncoplastic reduction mammoplasty have become invaluable techniques in treating large-breasted patients with ptosis who require some additional skin resection (Figures 2 and 3).²⁹⁻³¹ Tumor location dictates the incision pattern, as there are many possible options. Oncoplastic reduction mammoplasty provides the added benefit of a symmetrizing contralateral reduction, which improves the overall cosmetic outcome.^{5,32} This technique enables wide tumor resections,^{4,33} which extends the option for BCT^{1,2} without compromising oncologic safety.^{3,34} Additionally, in women who require RT, this technique can be used as a strategy for reducing complication rates.³

Postmastectomy Reconstruction

Mastectomy can be categorized into 4 types: simple, skin-sparing, nipple-sparing, and total skin-sparing. In simple mastectomy, all of the breast parenchyma, NAC, and excess breast skin are removed. Skin-sparing mastectomy preserves the skin envelope but removes the NAC. In nipple-sparing mastectomy, the skin and NAC are preserved. Finally, in total skin-sparing mastectomy, the entire skin envelope and NAC are preserved, and the nipple tissue beneath the NAC is completely cored out.^{35,36} Reconstruction following mastectomy is either implant-based, autologous tissue-based, or a combination of the 2. Abdominally based flaps are the preferred autologous tissue for breast reconstruction given their reliability and tissue bulk. These flaps may be rotated on a vascular pedicle, thus maintaining their original blood supply, or may be transferred as free flaps, which require a microvascular anastomosis to provide new blood flow. Transverse rectus abdominus myocutaneous (TRAM) flaps may be used as pedicled flaps or as free flaps. However, these put patients at risk for developing abdominal hernias because muscle and fascia are removed from the abdomen. Muscle-sparing TRAM flaps have minimized this donor site morbidity. Going one step further,

deep inferior epigastric perforator (DIEP) flaps were developed, which leave the entire abdominal musculature and fascia intact.

The initial decision when planning reconstruction is determining when the reconstruction should be performed, either immediately at the time of mastectomy or in a delayed fashion following healing from mastectomy. Delayed breast reconstruction offers suboptimal aesthetic outcomes, as it does not allow for maintenance of the shape of the original breast skin envelope. Furthermore, this technique does not allow for aesthetic preservation of the NAC position, due to postmastectomy skin healing and contraction on the chest wall, and is thus only compatible with skin-sparing mastectomy techniques (non-nipple-sparing).

Overall, the reported outcome rates for delayed reconstruction are highly dependent on whether the patient received postmastectomy RT.³⁷⁻⁴⁰ Quoted complication rates for delayed reconstruction range from 31% to 41%.^{41,42} Patients who undergo delayed reconstruction and do not require RT have lower complication rates than those who undergo immediate reconstruction or those who do undergo postmastectomy RT. In patients who do require RT, many authors advocate delaying definitive reconstruction until the RT course has been completed.^{43,45}

Immediate prosthetic breast reconstruction is the authors' preferred technique, as it offers superior aesthetic outcomes and allows for preservation and aesthetic positioning of the NAC on the reconstructed breast mound. Most commonly, this is done as a 2-stage process, with a tissue expander placed at the time of mastectomy and only partially filled. Over the following months, the tissue expander is slowly inflated to redevelop the breast pocket. Following completion of expansion, the patient undergoes operative exchange of the expander for a permanent breast implant.

Complications specific to prosthetic reconstruction include capsular contracture, implant malposition, implant exposure, and implant deflation.⁴² In cases of immediate prosthetic re-

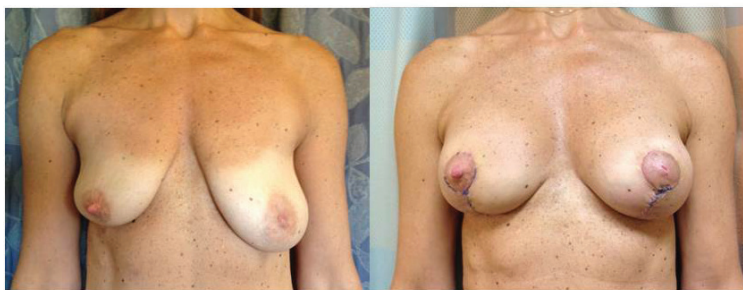construction, the reported infection rate is 7% to 13% in the nonradiated population.⁴⁶ The majority of these cases resolve with antibiotic treatment. Cases of cellulitis generally resolve with a course of outpatient antibiotic therapy, while deeper-tissue infections may require intravenous (IV) antibiotics for resolution. Ultimately, 3% of patients will require an operative washout for resolution of infection. The reported explantation rates range from 2% to 5%, and this includes explantation for all indications (ie, infection, expander/implant exposure, and capsular contracture).

The addition of postmastectomy RT significantly alters the outcomes profile of immediate breast reconstruction. This is due to the significant reduction in microvascular skin circulation induced by external-beam radiation therapy (EBRT) and its subsequent effect on healing and antibiotic delivery to the skin envelope. In this patient cohort, rates of infection range from 22% to 26%, with cellulitis the predominant finding in the vast majority of cases. Ultimately, the explantation rate in this population varies widely. Sbitany et al⁴⁶ and Spear et al⁴⁷ reported overall failure rates in the population undergoing immediate prosthetic reconstruction with postmastectomy RT of 17.7% and 21.4%, respectively. The Italian experience reported by Nava and colleagues⁴⁸ indicated a 40% failure rate in the same population.

The vastly different reported failure rates in the radiated population are likely multifactorial, but one caveat that has been reported to significantly influence complication rates is the use of acellular dermal matrix (ADM) to cover the prosthesis at the time of placement. ADM is decellularized human or animal tissue that can be safely placed within the breasts over a device, and revascularizes to provide added coverage and protection over the implant. Seth et al⁴⁹ reported a significant reduction in implant-related complications in the setting of EBRT when ADM was used to cover the implant versus when no ADM was used. Similar findings have been reported by Spear et al⁴⁷ and Sbitany et al.⁴⁶

The effects of chemotherapy on immediate prosthetic breast reconstruction outcomes reported in the literature are similarly wide ranging and conflicting.^{50,51} However, the majority of studies show women who receive chemotherapy do not have higher overall complication rates.^{52,53} Donker et al⁵³ analyzed the effect of neoadjuvant chemotherapy on complications in women undergoing skin-sparing mastectomy and immediate prosthetic reconstruction. Surprisingly, they found that the overall rate of short-term postoperative complications was significantly less among neoadjuvantly treated women (15% vs. 29%; $P = .042$), but this did not reduce the rate of prostheses lost (8% vs 11%; $P = .566$). The higher complication rate in the control group was primarily influenced by higher rates of skin necrosis. The in-

FIGURE 2.



A woman who underwent mastopexy with subpectoral implants following partial mastectomy of the right breast. Preoperative (left) and postoperative (right) photos.

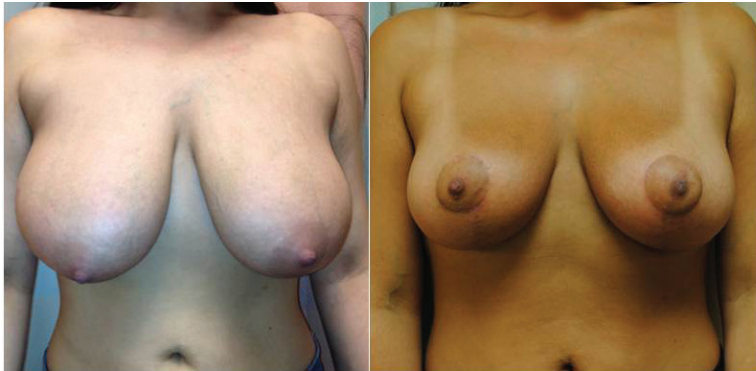vestigators attributed this reduced incidence of complications in neoadjuvant patients to their younger age, fewer comorbidities, and lower incidence of smoking.

A systematic review performed by Oh et al⁵⁰ assessed the impact of chemotherapy on reconstructive outcomes in immediate breast reconstruction. Several studies found that the use of adjuvant chemotherapy after immediate reconstruction negatively impacted reconstructive outcomes, with reported reconstructive failure rates of up to 38% in the adjuvant chemotherapy group⁵⁴ and overall higher complication rates.⁵⁵ However, the majority of studies found no difference in complication rates or reconstructive failures in those who received chemotherapy.⁵⁶⁻⁵⁸ Overall, Hu et al concluded that neoadjuvant chemotherapy did not negatively impact reconstructive outcomes, but may delay surgical timing.⁵⁹

With regard to initiation of adjuvant chemotherapy following mastectomy and immediate breast reconstruction, the reported delays in treatment initiation vary widely in the literature.⁶⁰ Although not commonly observed, women who have had mastectomy and tissue expander placement may have a slight delay in starting adjuvant chemotherapy.^{61,62} Yule et al⁶¹ recorded delays of more than 1 month in 2 of 23 patients requiring adjuvant chemotherapy, out of a total of 46 patients treated with mastectomy and immediate breast reconstruction. Conversely, numerous other studies compared time to onset of chemotherapy after mastectomy and immediate breast reconstruction with control groups treated by mastectomy alone (no reconstruction) and revealed no significant difference; chemotherapy commenced, on average, 41 to 53 days after surgery.^{51,52,63}

It is our clinical experience that immediate breast reconstruction does not delay the initiation of adjuvant chemotherapy when reconstruction is performed with placement of a tissue expander at the time of mastectomy. Great care is taken not to overfill the expander at the time of placement. This reduces the tension on the overlying skin envelope as it heals, and thus re-

FIGURE 3.



A woman who underwent mastopexy with subpectoral implants following partial mastectomy of the right breast. Preoperative (left) and postoperative (right) photos.

be performed during chemotherapy treatment, but rather that expansion should proceed following completion of all infusions.

For patients undergoing postmastectomy EBRT, we recommend full and complete expansion of the tissue expander prior to radiation delivery. We wait to exchange the tissue expander for a silicone implant until RT has finished. We recommend waiting 6 months after completion of RT for this exchange operation, as this has been shown to reduce wound dehiscence and implant extrusion rates.⁶⁴

Conclusion

The management of breast cancer has changed dramatically over the last 30 years. Improvements in neoadjuvant therapy and surgical techniques have allowed more women to be candidates for BCT. As a result, oncoplastic surgical techniques were developed and subsequently became invaluable

to the field of reconstructive surgery, as well as to the comprehensive treatment of breast cancer. Oncoplastic techniques minimize breast deformities following cancer resection and treatment, while maintaining equivalent oncologic outcomes.

Additionally, modifications to mastectomy techniques have significantly improved aesthetic results and patient satisfaction, and as a result, there has been a rise in prophylactic and bilateral mastectomies. Surgeons routinely preserve the entire breast envelope and NAC. The primary focus in implant and autologous-based reconstruction is recreating a breast that appears and feels natural. Outcomes research has enabled us to identify the risk-inducing effects of chemotherapy and RT on breast reconstruction. Based on these outcomes studies, we have identified various timing and technique algorithms to help minimize the risk in postmastectomy breast reconstruction.

duces the incidence of wound dehiscence and skin necrosis that may delay the initiation of chemotherapy.

A review of our institutional database was also performed to assess the effects of trastuzumab and hormonal therapy on patients undergoing total skin-sparing mastectomy and immediate tissue expander placement for reconstruction. With regard to the complications assessed (nipple necrosis, skin necrosis, infection, expander/implant loss or removal), no statistically significant differences were found between the patients treated with trastuzumab and the patients not treated. A similar review of patients treated with hormone therapy showed statistical differences only in the incidence of seroma (relative risk [RR], 3.43; $P = .007$) and minor skin necrosis (RR, 2.97; $P = .021$). The incidence of all other complications assessed in patients taking hormonal therapy treatment was statistically equivalent to those patients not being treated.

Recommendations

Based on our clinical experience and data, we advocate specific timing regimens and algorithms for patients undergoing immediate prosthetic breast reconstruction at the time of mastectomy. We have found that these timing schemes help to minimize surgical risk. For those patients undergoing neoadjuvant chemotherapy, we recommend surgery 1 month after the final infusion is administered. Furthermore, for those patients on hormonal therapy, we recommend patients discontinue therapy 2 to 3 weeks before surgery to reduce the risk of minor skin necrosis and wound dehiscence. We advocate waiting 4 to 6 weeks prior to initiation of chemotherapy infusions for patients requiring adjuvant chemotherapy after mastectomy and prosthetic reconstruction. Additionally, we recommend that no tissue expansion

able to the field of reconstructive surgery, as well as to the comprehensive treatment of breast cancer. Oncoplastic techniques minimize breast deformities following cancer resection and treatment, while maintaining equivalent oncologic outcomes. Additionally, modifications to mastectomy techniques have significantly improved aesthetic results and patient satisfaction, and as a result, there has been a rise in prophylactic and bilateral mastectomies. Surgeons routinely preserve the entire breast envelope and NAC. The primary focus in implant and autologous-based reconstruction is recreating a breast that appears and feels natural. Outcomes research has enabled us to identify the risk-inducing effects of chemotherapy and RT on breast reconstruction. Based on these outcomes studies, we have identified various timing and technique algorithms to help minimize the risk in postmastectomy breast reconstruction.

Acknowledgments: The authors thank Pamela Derish for her review of the manuscript.

Affiliations: Merisa L. Piper, MD, and Hani Sbitany, MD, FACS, are from the Division of Plastic and Reconstructive Surgery, Department of Surgery, University of California, San Francisco, San Francisco, CA.

Disclosures: Dr Piper has no relevant financial conflicts of interest to disclose. Dr Sbitany is a member of the Speakers' Bureau for LifeCell, Inc.

Address correspondence to: Hani Sbitany, MD, FACS, Division of Plastic Surgery, University of California, San Francisco, 505 Parnassus Ave, Suite M593, San Francisco, CA 94143. Phone: (415) 353-4285; fax: (415) 353-4320; email: Hani.Sbitany@ucsf.edu.

REFERENCES

1. Chang EI, Peled AW, Foster RD, et al. Evaluating the feasibility of extended partial mastectomy and immediate reduction mammoplasty reconstruction as an alternative to mastectomy. *Ann Surg.* 2012;255(6):1151-1157.
2. Clough KB, Lewis JS, Couturaud B, et al. Oncoplastic techniques allow extensive resections for breast-conserving therapy of breast carcinomas. *Ann Surg.* 2003;237(1):26-34.
3. Peled AW, Sbitany H, Foster RD, Esserman LJ. Oncoplastic mammoplasty as a strategy for reducing reconstructive complications associated with postmastectomy radiation therapy. *Breast J.* 2014;20(3):302-307.
4. Losken A, Pinell-White X, Hart AM, et al. The oncoplastic reduction approach to breast conservation therapy: benefits for margin control. *Aesthet Surg J.* 2014;34(8):1185-1191.
5. Clough KB, Ihrai T, Oden S, et al. Oncoplastic surgery for breast cancer based on tumour location and a quadrant-per-quadrant atlas. *Br J Surg.* 2012;99(10):1389-1395.
6. Veiga DF, Veiga-Filho J, Ribeiro LM, et al. Evaluations of aesthetic outcomes of oncoplastic surgery by surgeons of different gender and specialty: a prospective controlled study. *Breast.* 2011;20(5):407-412.
7. Barnea Y, Inbal A, Barsuk D, et al. Oncoplastic reduction using the vertical scar superior-medial pedicle pattern technique for immediate partial breast reconstruction. *Can J Surg.* 2014;57(4):E134-E140.
8. Chan SW, Cheung PS, Lam SH. Cosmetic outcome and percentage of breast volume excision in oncoplastic breast conserving surgery. *World J Surg.* 2010;34(7):1447-1452.
9. Losken A, Dugal CS, Styblo TM, Carlson GW. A meta-analysis comparing breast conservation therapy alone to the oncoplastic technique. *Ann Plast Surg.* 2014;72(2):145-149.
10. Warren Peled A, Foster RD, Stover AC, et al. Outcomes after total skin-sparing mastectomy and immediate reconstruction in 657 breasts. *Ann Surg Oncol.* 2012;19(11):3402-3409.
11. Spear SL, Hannan CM, Willey SC, Cocilovo C. Nipple-sparing mastectomy. *Plast Reconstr Surg.* 2009;123(6):1665-1673.
12. Garcia-Etienne CA, Cody HS III, Disa JJ, et al. Nipple-sparing mastectomy: initial experience at the Memorial Sloan-Kettering Cancer Center and a comprehensive review of literature. *Breast J.* 2009;15(4):440-449.
13. Chen CM, Disa JJ, Sacchini V, et al. Nipple-sparing mastectomy and immediate tissue expander/implant breast reconstruction. *Plast Reconstr Surg.* 2009;124(6):1772-1780.
14. Wang F, Peled AW, Garwood E, et al. Total skin-sparing mastectomy and immediate breast reconstruction: an evolution of technique and assessment of outcomes. *Ann Surg Oncol.* 2014;21(10):3223-3230.
15. Spear SL, Willey SC, Feldman ED, et al. Nipple-sparing mastectomy for prophylactic and therapeutic indications. *Plast Reconstr Surg.* 2011;128(5):1005-1014.
16. Peled AW, Duralde E, Foster RD, et al. Patient-reported outcomes and satisfaction after total skin-sparing mastectomy and immediate expander-implant reconstruction. *Ann Plast Surg.* 2014;72(suppl 1):S48-S52.
17. Cemal Y, Albornoz CR, Disa JJ, et al. A paradigm shift in U.S. breast reconstruction: part 2: the influence of changing mastectomy patterns on reconstructive rate and method. *Plast Reconstr Surg.* 2013;131(3):320e-326e.
18. Fisher B, Anderson S, Bryant J, et al. Twenty-year follow-up of a randomized trial comparing total mastectomy, lumpectomy, and lumpectomy plus irradiation for the treatment of invasive breast cancer. *N Engl J Med.* 2002;347(16):1233-1241.
19. Fisher B, Jeong JH, Anderson S, et al. Twenty-five-year follow-up of a randomized trial comparing radical mastectomy, total mastectomy, and total mastectomy followed by irradiation. *N Engl J Med.* 2002;347(8):567-575.
20. Piper M, Peled AW, Foster RD, et al. Total skin-sparing mastectomy: a systematic review of oncologic outcomes and postoperative complications. *Ann Plast Surg.* 2013;70(4):435-437.
21. Favourable and unfavourable effects on long-term survival of radiotherapy for early breast cancer: an overview of the randomised trials. *Lancet.* 2000;355(9217):1757-1770.
22. Barry M, Kell MR. Radiotherapy and breast reconstruction: a meta-analysis. *Breast Cancer Res. Treat.* 2011;127:15-22.
23. Kronowitz SJ. State of the art and science in postmastectomy breast reconstruction. *Plast Reconstr Surg.* 2015;135(4):755e-771e.
24. Slavin SA, Love SM, Sadowsky NL. Reconstruction of the radiated partial mastectomy defect with autogenous tissues. *Plast Reconstr Surg.* 1992;90(5):854-865; discussion 866-869.
25. Losken A, Hamdi M. Partial breast reconstruction: Current perspectives. *Plast Reconstr Surg.* 2009;124(3):722-736.
26. Kronowitz SJ, Kuerer HM, Buchholz TA, et al. A management algorithm and practical oncoplastic surgical techniques for repairing partial mastectomy defects. *Plast Reconstr Surg.* 2008;122(6):1631-1647.
27. Clough KB, Kroll SS, Audretsch W. An approach to the repair of partial mastectomy defects. *Plast Reconstr Surg.* 1999;104(2):409-420.
28. Papp C, Wechselberger G, Schoeller T. Autologous breast reconstruction after breast-conserving cancer surgery. *Plast Reconstr Surg.* 1998;102(6):1932-1936; discussion 1937-1938.
29. Macmillan RD, James R, Gale KL, McCulley SJ. Therapeutic mammoplasty. *J Surg Oncol.* 2014;110(1):90-95.
30. Newman LA, Kuerer HM, McNeese MD, et al. Reduction mammoplasty improves breast conservation therapy in patients with macromastia. *Am J Surg.* 2001;181(3):215-220.
31. Spear SL, Pelletiere CV, Wolfe AJ, et al. Experience with reduction mammoplasty combined with breast conservation therapy in the treatment of breast cancer. *Plast Reconstr Surg.* 2003;111(3):1102-1109.

32. Chang E, Johnson N, Webber B, et al. Bilateral reduction mammoplasty in combination with lumpectomy for treatment of breast cancer in patients with macromastia. *Am J Surg*. 2004;187(5):647-650; discussion 650-651.
33. Kaur N, Petit JY, Rietjens M, et al. Comparative study of surgical margins in oncoplastic surgery and quadrantectomy in breast cancer. *Ann Surg Oncol*. 2005;12(7):539-545.
34. Piper M, Peled AW, Sbitany H, Foster R, Esserman L, Price ER. A comparison of mammographic findings following oncoplastic mammoplasty and lumpectomy without reconstruction [published online May 21, 2015]. *Ann Surg Oncol*.
35. Wijayanayagam A, Kumar AS, Foster RD, Esserman LJ. Optimizing the total skin-sparing mastectomy. *Arch Surg*. 2008;143(1):38-45; discussion 45.
36. Garwood ER, Moore D, Ewing C, et al. Total skin-sparing mastectomy: complications and local recurrence rates in 2 cohorts of patients. *Ann Surg*. 2009;249(1):26-32.
37. Ascherman JA, Hanasono MM, Newman MI, Hughes DB. Implant reconstruction in breast cancer patients treated with radiation therapy. *Plast Reconstr Surg*. 2006;117(2):359-365.
38. Berry T, Brooks S, Sydow N, et al. Complication rates of radiation on tissue expander and autologous tissue breast reconstruction. *Ann Surg Oncol*. 2010;17(Suppl 3):202-210.
39. Tsoi B, Ziolkowski NI, Thoma A, et al. Safety of tissue expander/implant versus autologous abdominal tissue breast reconstruction in postmastectomy breast cancer patients: a systematic review and meta-analysis. *Plast Reconstr Surg*. 2014;133(2):234-249.
40. Alderman A, Gutowski K, Ahuja A, Gray D, Postmastectomy Expander Implant Breast Reconstruction Guideline Work Group. ASPS clinical practice guideline summary on breast reconstruction with expanders and implants. *Plast Reconstr Surg*. 2014;134(4):648e-655e.
41. Alderman AK, Wilkins EG, Kim HM, Lowery JC. Complications in postmastectomy breast reconstruction: two-year results of the Michigan Breast Reconstruction Outcome Study. *Plast Reconstr Surg*. 2002;109(7):2265-2274.
42. Sullivan SR, Fletcher DR, Isom CD, Isik FF. True incidence of all complications following immediate and delayed breast reconstruction. *Plast Reconstr Surg*. 2008;122(1):19-28.
43. Tran NV, Evans GR, Kroll SS, et al. Postoperative adjuvant irradiation: effects on tranverse rectus abdominis muscle flap breast reconstruction. *Plast Reconstr Surg*. 2000;106(2):313-317; discussion 318-320.
44. Rogers NE, Allen RJ. Radiation effects on breast reconstruction with the deep inferior epigastric perforator flap. *Plast Reconstr Surg*. 2002;109(6):1919-1924; discussion 1925-1926.
45. Spear SL, Ducic I, Low M, Cuoco F. The effect of radiation on pedicled TRAM flap breast reconstruction: outcomes and implications. *Plast Reconstr Surg*. 2005;115(1):84-95.
46. Sbitany H, Wang F, Peled AW, et al. Immediate implant-based breast reconstruction following total skin-sparing mastectomy: defining the risk of preoperative and postoperative radiation therapy for surgical outcomes. *Plast Reconstr Surg*. 2014;134(3):396-404.
47. Spear SL, Seruya M, Rao SS, et al. Two-stage prosthetic breast reconstruction using AlloDerm including outcomes of different timings of radiotherapy. *Plast Reconstr Surg*. 2012;130(1):1-9.
48. Nava MB, Pennati AE, Lozza L, et al. Outcome of different timings of radiotherapy in implant-based breast reconstructions. *Plast Reconstr Surg*. 2011;128(2):353-359.
49. Seth AK, Hirsch EM, Fine NA, Kim JY. Utility of acellular dermis-assisted breast reconstruction in the setting of radiation: a comparative analysis. *Plast Reconstr Surg*. 2012;130(4):750-758.
50. Oh E, Chim H, Soltanian HT. The effects of neoadjuvant and adjuvant chemotherapy on the surgical outcomes of breast reconstruction. *J Plast Reconstr Aesthet Surg*. 2012;65(10):e267-e280.
51. Allweis TM, Boisvert ME, Otero SE, et al. Immediate reconstruction after mastectomy for breast cancer does not prolong the time to starting adjuvant chemotherapy. *Am J Surg*. 2002;183(3):218-221.
52. Caffo O, Cazzolli D, Scalet A, et al. Concurrent adjuvant chemotherapy and immediate breast reconstruction with skin expanders after mastectomy for breast cancer. *Breast Cancer Res Treat*. 2000;60(3):267-275.
53. Donker M, Hage JJ, Woerdeman LA, et al. Surgical complications of skin sparing mastectomy and immediate prosthetic reconstruction after neoadjuvant chemotherapy for invasive breast cancer. *Eur J Surg Oncol*. 2012;38(1):25-30.
54. Mitchem J, Herrmann D, Margenthaler JA, Aft RL. Impact of neoadjuvant chemotherapy on rate of tissue expander/implant loss and progression to successful breast reconstruction following mastectomy. *Am J Surg*. 2008;196(4):519-522.
55. Mehrara BJ, Santoro TD, Arcilla E, et al. Complications after microvascular breast reconstruction: experience with 1195 flaps. *Plast Reconstr Surg*. 2006;118(5):1100-1109.
56. Zweifel-Schlatter M, Darhouse N, Roblin P, et al. Immediate microvascular breast reconstruction after neoadjuvant chemotherapy: complication rates and effect on start of adjuvant treatment. *Ann Surg Oncol*. 2010;17(11):2945-2950.
57. McCarthy CM, Mehrara BJ, Riedel E, et al. Predicting complications following expander/implant breast reconstruction: an outcomes analysis based on preoperative clinical risk. *Plast Reconstr Surg*. 2008;121(6):1886-1892.
58. Azzawi K, Ismail A, Earl H, et al. Influence of neoadjuvant chemotherapy on outcomes of immediate breast reconstruction. *Plast Reconstr Surg*. 2010;126(1):1-11.
59. Hu Y, Weeks CM, In H, et al. Impact of neoadjuvant chemotherapy on breast reconstruction. *Cancer*. 2011;117(13):2833-2841.
60. Taylor CW, Horgan K, Dodwell D. Oncological aspects of breast reconstruction. *Breast*. 2005;14(2):118-130.

61. Yule GJ, Concannon MJ, Croll G, Puckett CL. Is there liability with chemotherapy following immediate breast construction? *Plast Reconstr Surg.* 1996;97(5):969-973.
62. Hoffman JP, Kusiak J, Boraas M, et al. Risk factors for immediate prosthetic postmastectomy reconstruction. *Am Surg.* 1991;57(8):514-521; discussion 522.
63. Taylor CW, Kumar S. The effect of immediate breast reconstruction on adjuvant chemotherapy. *Breast.* 2005;14(1):18-21.
64. Peled AW, Foster RD, Esserman LJ, et al. Increasing the time to expander-implant exchange after postmastectomy radiation therapy reduces expander-implant failure. *Plast Reconstr Surg.* 2012;130(3):503-509.